



New York Veterinary Specialty and Emergency Center

2233 Broadhollow Road, Farmingdale, NY 11735

www.nyvsc.com vets@nyvsc.com

631-694-3400 fax 631-694-3401

Quality Medicine with a Caring Attitude

Patella Luxation

The dogs knee cap or patella can be dislocated either to the inside (medial) or the outside (lateral). The more common is medial This is an inherited problem and usually shows up around 6-7 months of age. The luxations are graded 1-4, 1 being the least severe and 4 the most.

Grade 1: The knee cap can be dislocated manually but rarely dislocates on its own and usually there is no lameness. It is usually an incidental finding and rarely is treatment necessary.

Grade 2: The knee cap dislocated on its own but returns to its normal position on its own. This grade can be subdivided into Grade 2 and Grade 2+ depending on frequency and ease of luxation. Lameness varies from occasionally holding the leg up but normal in between, to a steady mild lameness. Often both knees are affected and the dogs are reluctant or unable to jump up on objects or chairs. They often appear bow legged.

Plain Grade 2 MPL's are often not lame and may not require surgery while Grade 2+ are usually lame and surgery is the only corrective treatment. Some surgeons will recommend surgery for all Grade 2 luxations to prevent damage to the cartilage on the patella leading to arthritis later on. Some dogs never become lame.

Grade 3: The knee cap is luxated all the time but still can be replaced or reduced manually. If left untreated the cartilage will be eroded from rubbing on the bone of the femur. Treatment is surgery and is recommended.

Grade 4: The knee cap is permanently dislocated and cannot be reduced without surgery. Some Grade 4 MPL's are just Grade 3 that has been out too long but there is a group of severe dislocations that occur in young dogs where the knee (stifle) joint is distorted and the muscles foreshortened. Often these dogs cannot straighten their leg at all. These cases are difficult to correct and the prognosis is not as good for a normally functioning leg even after surgery.

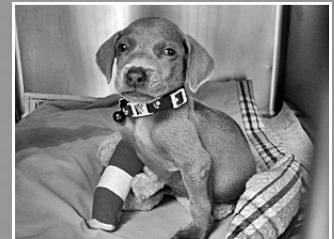The underlying cause of a dislocating patella is a malalignment of the knee joint. The kneecap is attached to 4 muscles called the quadriceps on top and the shin bone or tibia via the patella ligament on the bottom. When the muscles contracts tension is placed on the patella and its attachment to the tibia causing the leg to straighten. If a line drawn



24 Hour Emergency Services

Specialists On Call

24 Hour ICU Care



High Speed Spiral CT

Stem Cell Therapy

Ultrasound

ShockWave® Therapy

Gait Analysis

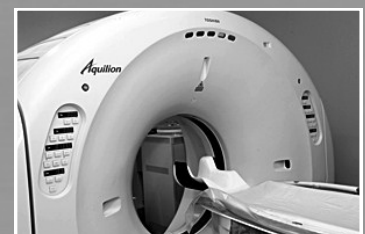Digital X-ray

In-House Diagnostic Imaging

Radiologist Consults

Endoscopy

Cystoscopy



Quality Medicine with a Caring Attitude

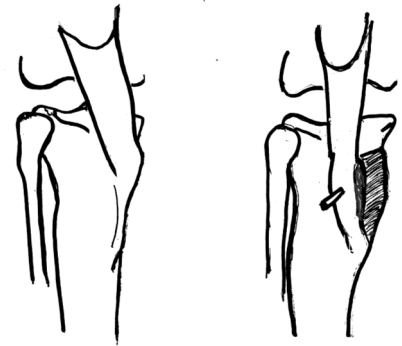
Patella Luxation (continued)



from the beginning of the muscle to the point of attachment to the tibia does not go through the groove that the patella rides in it will tend to dislocate. This can be caused by curving of the bones (bowlegged) Fig.2a. or rotation of the point of attachment. Fig 1a. Also some dogs stand with a very straight leg and the kneecap rides above the groove (Patella Alta) Fig.4 and is very unstable.

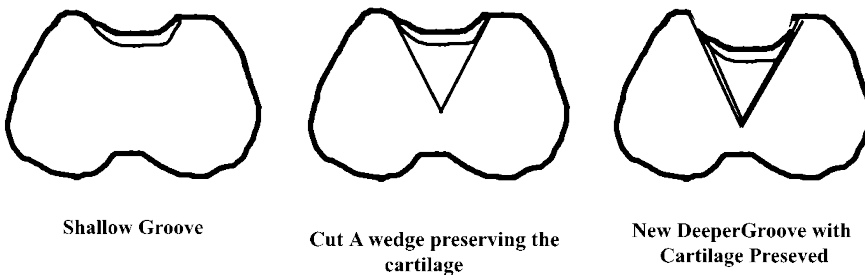
SURGERIES:

Surgeries should be aimed at correcting the malalignment. The most common case is the tibial crest rotated to the inside Fig. 3a. In this case the crest is detached and moved to the outside and reattached there with pins or wires or both Fig.3b. If the luxation is lateral (to the outside) then the crest is moved to the inside. For those dogs where the patella rides above the groove often the crest is also moved down as well as outside to pull the kneecap into the groove.



Tibial Crest Transplant to realign the Knee cap

Often the groove is not completely formed and is deepened as part of the repair. This can be accomplished by removing the cartilage and bone to make a rectangular slot fig. which fills in with fibrocartilage. Or a wedge or section of cartilage and bone is lifted and the bed below is deepened and then the bone/cartilage piece is replaced. This preserves the cartilage and is called a wedge trochleoplasty.



Shallow Groove

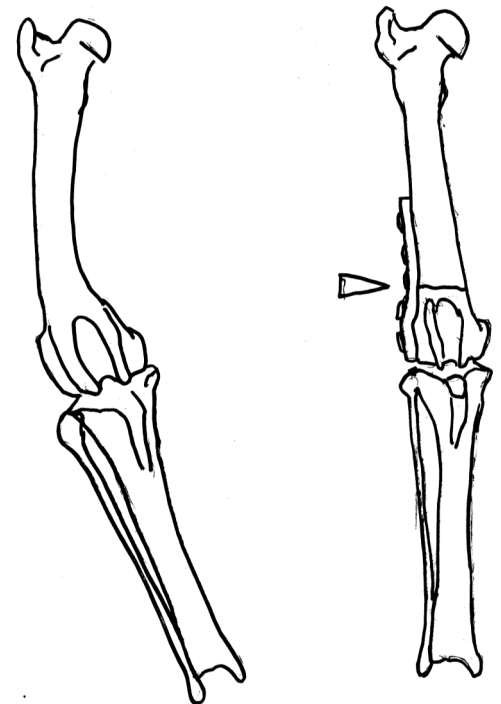
Cut A wedge preserving the cartilage

New Deeper Groove with Cartilage Preserved

Finally the tissues on the side of the luxation are loosened with relief incisions and the tissue on the opposite side are tightened or imbricated.

In some more complicated cases a bone graft is harvested from the pelvis and used to build up the side of the groove where it has been worn down by the luxating patella. In cases of patella Alta. where the tibial crest cannot be advanced this graft can be used to extend the groove.

If the bones of the leg (femur and tibia) are curved or twisted then it is necessary to cut the bones and straighten them out Fig.2a & 2b. Bone plates are used to hold them together until the bones heal.



a wedge of bone is removed to straightnen the leg